

# Trigeminal neuralgia secondary to basilar invagination responsive to botulinum toxin type A. Case report

## *Neuralgia do trigêmeo secundária à invaginação basilar responsiva a toxina botulínica do tipo A. Relato de caso*

João Vitor Andrade Fernandes<sup>1</sup>, Raissa Nery de Luna Freire Leite<sup>2</sup>, Adriana Meira Tiburtino Nepomuceno<sup>3</sup>, Maurus Marques de Almeida Holanda<sup>4</sup>, Alex Tiburtino Meira<sup>4</sup>

<https://doi.org/10.5935/2595-0118.20240050-en>

### ABSTRACT

**BACKGROUND AND OBJECTIVES:** Trigeminal neuralgia (TN) is a headache characterized by paroxysmal episodes of intense pain in the facial region. TN can occur secondary to structural mechanisms, such as vascular compression of the trigeminal nerve root. Basilar invagination (BI) is a malformation of the craniovertebral junction characterized by invagination of the odontoid process of the axis through the foramen magnum into the posterior fossa, and 1% of cases may present associated TN. This article presents a clinical case of TN secondary to BI and vascular compression of the trigeminal nerve root, which responded only to treatment with botulinum toxin type A.

**CASE REPORT:** A 34-year-old patient with a clinical presentation consistent with TN for approximately 12 years. The symptoms were debilitating and impacted the quality of life, culminating in constant insomnia, severe depression, and suicidal

thoughts. Treatment with botulinum toxin type A was fundamental in managing this patient's pain.

**CONCLUSION:** The case reported here demonstrated the therapeutic success of treatment with botulinum toxin type A in a complex and refractory case of pain syndrome.

**Keywords:** Basilar invagination, Botulinum toxin A, Trigeminal neuralgia.

### RESUMO

**JUSTIFICATIVA E OBJETIVOS:** Neuralgia do trigêmeo (NT) é uma cefaleia caracterizada por episódios paroxísticos de dores intensas na região da face. A NT pode ocorrer secundariamente a mecanismos estruturais, como a compressão vascular da raiz do nervo trigêmeo. A invaginação basilar (IB) é uma má formação da junção craniovertebral caracterizada por invaginação do processo odontóide do Axis através do forâmen magno na fossa posterior, e 1% dos casos podem apresentar NT associada. Este artigo apresenta um caso clínico de NT secundária a IB e compressão vascular da raiz do nervo trigêmeo, que foi responsiva apenas ao tratamento com toxina botulínica tipo A.

**RELATO DO CASO:** Paciente do sexo masculino, 34 anos de idade com quadro clínico compatível com NT há aproximadamente 12 anos. Os sintomas eram debilitantes e impactavam na qualidade de vida, culminando em insônia constante, depressão grave e pensamentos suicidas. O tratamento com toxina botulínica tipo A foi fundamental no tratamento da dor deste paciente.

**CONCLUSÃO:** O caso reportado evidenciou o sucesso terapêutico do tratamento com toxina botulínica tipo A em um caso complexo e refratário de síndrome dolorosa.

**Descritores:** Invaginação basilar, Neuralgia do trigêmeo, Toxina botulínica do tipo A.

João Vitor Andrade Fernandes – <https://orcid.org/0000-0002-0619-4796>;  
Raissa Nery de Luna Freire Leite – <https://orcid.org/0000-0001-5657-8838>;  
Adriana Meira Tiburtino Nepomuceno – <https://orcid.org/0000-0002-0814-1575>;  
Maurus Marques de Almeida Holanda – <https://orcid.org/0000-0003-2217-4434>;  
Alex Tiburtino Meira – <https://orcid.org/0000-0002-6685-7491>.

1. Federal University of Paraíba, Medicine Undergraduate, João Pessoa, PB, Brazil.
2. Nova Medical Diagnostic Imaging Center, João Pessoa, PB, Brazil.
3. Federal University of Paraíba, Professional Master's Programme in Gerontology, João Pessoa, PB, Brazil.
4. Federal University of Paraíba, Internal Department of Medicine, João Pessoa, PB, Brazil.

Submitted on April 14, 2024.

Accepted for publication on August 05, 2024.

Conflict of interests: none - Sponsoring sources:

### HIGHLIGHTS

- Trigeminal neuralgia (TN) can occur secondary to basilar invagination.
- TN is refractory to medical treatment in many cases.
- Botulinum toxin type A can be used as treatment in complex and refractory cases of TN.

Associate editor in charge: Oscar Cesar Pires

<https://orcid.org/0000-0002-7033-0764>

Correspondence to:

Alex Tiburtino Meira

E-mail: alex.meira@academico.ufpb.br



This is an open-access article distributed under the terms of the Creative Commons Attribution License.

lines (in the midsagittal plane) – is crucial<sup>1</sup>. This structural abnormality can lead to various clinical manifestations, including chronic headaches, myelopathy, sensory abnormalities, brainstem dysfunction, vascular compromise, and/or lower cranial nerve dysfunction<sup>1,2</sup>.

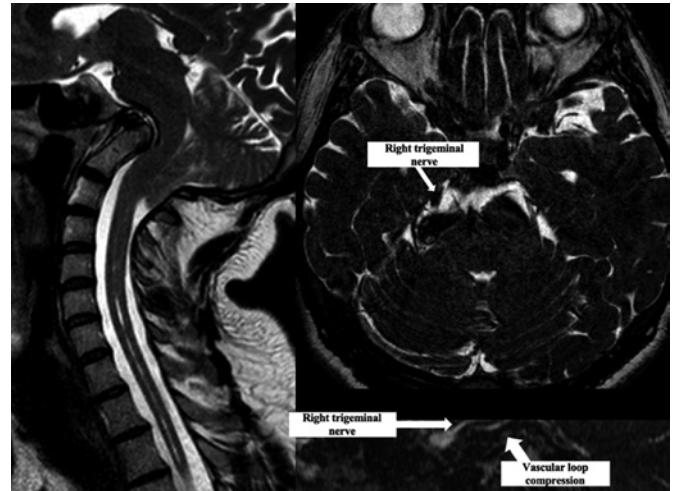Trigeminal neuralgia (TN) is a severe paroxysmal facial pain resembling electric shocks<sup>3,4</sup>. It occurs in approximately 1% of BI cases, with no definitive consensus on the optimal treatment modality established through randomized studies<sup>5,6</sup>. Classic TN typically arises from neurovascular compression, often involving the superior cerebellar artery pressing on the trigeminal nerve roots<sup>7</sup>. This compression induces demyelination, resulting in abnormal nerve firing. Subsequent changes include demyelination at the trigeminal nerve entry point, alterations in peripheral axons, and damage to Schwann cells and peripheral myelin<sup>8</sup>. The “Ignition Hypothesis” links these structural changes to sudden bursts of pain, suggesting that damaged neurons become overly excitable, prompting nearby neurons to follow suit, leading to heightened electrical activity and intensified pain signals due to proximity and damage to myelin sheaths<sup>9</sup>.

Moreover, compression from the odontoid process in the cervicobulbar region can trigger symptoms such as paresis, spasticity, vertigo, gait ataxia, appendicular abnormalities, and altered sensation, albeit rarely in conjunction with TN<sup>6-10</sup>. Managing these symptoms necessitates a comprehensive approach encompassing pharmacotherapy, surgical interventions, and rehabilitation strategies aimed at alleviating pain and optimizing compromised neurological function<sup>4,11</sup>.

This article presents a challenging clinical scenario involving a patient with TN secondary to basilar invagination and vascular compression on the trigeminal nerve root, refractory to optimized oral drugs, thereby precluding surgical intervention. Highlighting the inherent complexities of therapeutic decision-making, it is emphasized the pivotal role of Botulinum toxin type A therapy in pain management for this patient.

## CASE REPORT

Male patient, 34-year-old, presented to the outpatient neurology clinic with clinical symptoms consistent with trigeminal neuralgia (paroxysmal shock-like pains in the territory innervated by the right V2 and V3) persisting for approximately the last 12 years. Neuroimaging revealed basilar invagination and neurovascular conflict of the trigeminal nerve (Figure 1). During regular medical follow-up, attempts were made to optimize drug treatment, including some combinations of duloxetine (maximum dose achieved 120 mg/day), carbamazepine (1,200 mg/day), valproate (1,500 mg/day), lamotrigine (200 mg/day), and a recent trial of cannabidiol, without significant improvement. Surgical intervention was deemed inappropriate by a neurosurgeon. This debilitating condition severely impacted the patient’s quality of life, leading to suicidal ideation, severe depression, constant insomnia, and cessation of employment. Upon initial assessment at the botulinum toxin outpatient clinic, a physical examination revealed a short neck, allodynia,

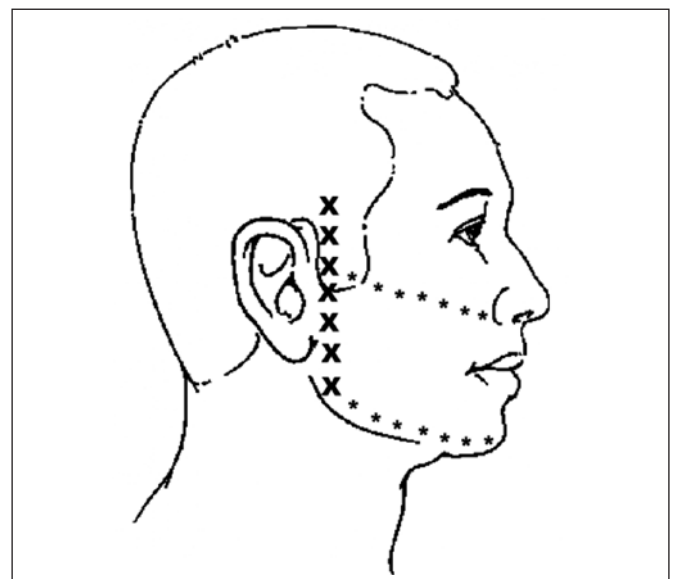


**Figure 1.** Basilar invagination and neurovascular conflict in a patient with trigeminal neuralgia refractory to optimized oral drugs over 12 years, who responded to botulinum toxin type A therapy.

Chiari malformation and syringomyelia can be observed.

hyperalgesia in the territories of the right V2 and V3, and signs of poor self-care. Treatment with botulinum toxin type A (Botox<sup>®</sup>) (BoNT/A) was initiated at a dose of 30 units, distributed subcutaneously along the territory of V2 and V3, according to figure 2, with a 2 cm distance between each point of application<sup>12</sup>. Remarkably, the patient experienced an 80% improvement in pain intensity (Visual Analogue Scale from 10/10 to 2/10) and frequency (from constant to few attacks in the day) following the first dose.

Furthermore, significant improvements were observed in quality of life (assessed by the Quality Of Life Scale from the American Chronic Pain Association), from 0 - meaning that the patient stays in bed all day and feels hopeless and helpless about



**Figure 2.** Schematic representation of the distribution of 30 units of botulinum toxin type A across the right V2 and V3 territories, with each injection spaced approximately 1-2 cm apart.

X = 2 units; \* = 1 unit.

life; going to 10 - meaning a normal quality of life), sleep (assessed subjectively), and mood (evaluated by the Beck Depression Inventory, going from 36 – severe depression, to 2 – normal), with the absence of suicidal ideation and resumption of employment. The results were observed since the 3rd day after the injections, and sustained benefits of BoNT/A therapy were achieved without adverse effects. Reapplications are conducted every three months, and the patient has already undergone three reapplications in total<sup>13</sup>. The patient continues to follow up with good clinical control, with each injection effect lasting approximately three months.

## DISCUSSION

In the management of TN, conventional drugs like carbamazepine and gabapentin are often employed at high doses. However, resistance or adverse effects frequently necessitate alternative treatment modalities, including cannabinoids, oral lacosamide, intranasal lidocaine, botulinum toxin, radiofrequency thermal lesioning, and gamma knife radiosurgery<sup>14-16</sup>. In this case, optimized pharmacotherapy failed to achieve significant pain control, underscoring the refractory nature of certain TN cases<sup>17,18</sup>.

Despite previous drugs interventions, treatment with BoNT/A demonstrated excellent efficacy, providing substantial pain relief and improving patient well-being, quality of life, and mood. This highlights the importance of considering unconventional approaches when standard treatments prove ineffective<sup>19</sup>. Recent studies have shown BoNT/A to effectively reduce pain by more than 50% in a significant proportion of TN patients at the 1- and 3-month follow-ups<sup>20</sup>.

Additionally, systematic review and meta-analysis of randomized controlled trials support the effectiveness and safety of BoNT/A in TN management<sup>21</sup>. Moreover, surgical interventions can occasionally lead to severe and often untreatable complications that might be even worse than the primary condition<sup>22</sup>. Furthermore, a study reported a recurrence of pain in about half of the patients within 2 years of percutaneous radiofrequency rhizotomy<sup>23</sup>.

While the exact mechanism of BoNT/A pain modulation remains elusive, several potential pathways include inhibition of neurotransmitter release such as substance P, glutamate, and calcitonin gene-related peptide, thus impeding protein extravasation and reducing pain sensitivity<sup>24-26</sup>. Botulinum toxin administration also interferes with the fusion process of synaptic vesicles and the cell membrane, affecting the transportation of various receptors, including those responsible for pain perception such as TRPV1 and TRPA1<sup>27,28</sup>.

Additionally, BoNT/A also can influence neurons in the dorsal root ganglia and spinal cord, thereby attenuating neuropathic pain and altering neuropeptide expression<sup>29</sup>. BoNT/A may indirectly affect central nervous system pain processing pathways through retrograde transport, inhibiting purinergic transmission and reducing early gene expression in neurons<sup>30-32</sup>. Finally, the interaction between BoNT/A and non-neuronal cells like satellite glial cells suggests an additional analgesic mechanism

by inhibiting glutamate release and inflammatory signaling pathways<sup>33,34</sup>. Though the precise mechanisms are not fully understood, BoNT's multifaceted approach offers promising avenues for pain relief in various conditions<sup>35</sup>.

## CONCLUSION

This case highlights the necessity for personalized therapeutic approaches to manage trigeminal neuralgia. The success of BoNT/A therapy in treating refractory pain syndromes underscores its potential as a valuable therapeutic alternative in TN management.

## AUTHORS' CONTRIBUTIONS

### João Vitor Andrade Fernandes

Conceptualisation, Writing - Preparation of the original, Writing - Review and Editing, Visualisation

### Raissa Nery de Luna Freire Leite

Writing - Review and Editing, Supervision, Visualisation

### Adriana Meira Tiburtino Nepomuceno

Writing - Review and Editing, Supervision, Visualisation

### Maurus Marques de Almeida Holanda

Writing - Review and Editing, Supervision, Visualisation

### Alex Tiburtino Meira

Data Collection, Conceptualisation, Project Management, Research, Methodology, Writing - Preparation of the original, Writing - Review and Editing, Supervision, Validation, Visualisation

## REFERENCES

- Smoker WR. Craniovertebral junction: normal anatomy, craniometry, and congenital anomalies. *Radiographics*. 1994;14(2):255-77.
- Goel A. Basilar invagination, Chiari malformation, syringomyelia: a review. *Neuro India*. 2009;57(3):235-46.
- Headache Classification Committee of the International Headache Society (IHS) The International Classification of Headache Disorders, 3rd Ed. *Cephalalgia*. 2018;38(1):1-211.
- Maarbjerg S, Di Stefano G, Bendtsen L, Cruccu G. Trigeminal neuralgia - diagnosis and treatment. *Cephalalgia*. 2017;37(7):648-57.
- de Almeida Holanda MM, Pereira Neto NG, de Moura Peixoto G, Pinheiro Santos RH. Trigeminal neuralgia secondary to basilar impression: a case report. *J Craniovertebr Junction Spine*. 2015;6(2):76-8.
- da Silva JA, da Silva EB. Basilar impression as a cause of trigeminal neuralgia: report of a case. *Arq Neuropsiquiatr*. 1982;40(2):165-9.
- Jones MR, Urits I, Ehrhardt KP, Cefalu JN, Kendrick JB, Park DJ, Cornett EM, Kaye AD, Viswanath O. A comprehensive review of trigeminal neuralgia. *Curr Pain Headache Rep*. 2019;23(10):74.
- Hilton DA, Love S, Gradidge T, Coakham HB. Pathological findings associated with trigeminal neuralgia caused by vascular compression. *Neurosurgery*. 1994;35(2):299-303
- Devor M, Amir R, Rappaport ZH. Pathophysiology of trigeminal neuralgia: the ignition hypothesis. *Clin J Pain*. 2002;18(1):4-13.
- Obrador S, Queimadelos VG, Soto M. Trigeminal neuralgia secondary to asymmetry of the petrous bone. Case report. *J Neurosurg*. 1970;33(5):596-8.
- Lambru G, Zakrzewska J, Matharu M. Trigeminal neuralgia: a practical guide. *Pract Neurol*. 2021;21(5):392-402.
- Türk Börü Ü, Duman A, Bölük C, Coşkun Duman S, Taşdemir M. Botulinum toxin in the treatment of trigeminal neuralgia: 6-Month follow-up. *Medicine (Baltimore)*. 2017;96(39):e8133.
- Colhado OC, Boeing M, Ortega LB. Botulinum toxin in pain treatment. *Rev Bras Anesthesiol*. 2009;59(3):366-81.
- Cruccu G, Truini A. Refractory trigeminal neuralgia. Non-surgical treatment options. *CNS Drugs*. 2013;27(2):91-6.
- Das B, Saha SP. Trigeminal neuralgia: current concepts and management. *J Indian Med Assoc*. 2001;99(12):704-9.

16. Yang AI, Mensah-Brown KG, Shekhtman EF, Kvint S, Wathen CA, Hitti FL, Alonso-Basanta M, Avery SM, Dorsey JF, YK Lee J. Gamma Knife radiosurgery for trigeminal neuralgia provides greater pain relief at higher dose rates. *J Radiosurg SBRT*. 2022;8(2):117-25
17. Jacques N, Karoutsos S, Marais L, Nathan-Denizot N. Quality of life after trigeminal nerve block in refractory trigeminal neuralgia: a retrospective cohort study and literature review. *J Int Med Res*. 2022;50(10):3000605221132027.
18. Thapa D, Ahuja V, Dass C, Verma P. Management of refractory trigeminal neuralgia using extended duration pulsed radiofrequency application. *Pain Physician*. 2015;18(3):E433-5.
19. Xu R, Xie ME, Jackson CM. Trigeminal neuralgia: current approaches and emerging interventions. *J Pain Res*. 2021;14:3437-63.
20. Tereshko Y, Valente M, Belgrado E, Dalla Torre C, Dal Bello S, Merlino G, Gigli GL, Lettieri C. The therapeutic effect of botulinum toxin type a on trigeminal neuralgia: are there any differences between type 1 versus type 2 trigeminal neuralgia? *Toxins (Basel)*. 2023;15(11):654.
21. Morra ME, Elgebaly A, Elmaraczy A, Khalil AM, Altibi AM, Vu TL, Mostafa MR, Huy NT, Hirayama K. Therapeutic efficacy and safety of botulinum toxin a therapy in trigeminal neuralgia: a systematic review and meta-analysis of randomized controlled trials. *J Headache Pain*. 2016;17(1):63.
22. Taylor JC, Brauer S, Espir ML. Long-term treatment of trigeminal neuralgia with carbamazepine. *Postgrad Med J*. 1981;57(663):16-8.
23. Taha JM, Tew JM Jr. Treatment of trigeminal neuralgia by percutaneous radiofrequency rhizotomy. *Neurosurg Clin N Am*. 1997;8(1):31-9.
24. Mustafa G, Anderson EM, Bokrand-Donatelli Y, Neubert JK, Caudle RM. Anti-nociceptive effect of a conjugate of substance P and light chain of botulinum neurotoxin type A. *Pain*. 2013;154(11):2547-53.
25. Chaddock JA, Purkiss JR, Duggan MJ, Quinn CP, Shone CC, Foster KA. A conjugate composed of nerve growth factor coupled to a non-toxic derivative of Clostridium botulinum neurotoxin type A can inhibit neurotransmitter release in vitro. *Growth Factors*. 2000;18(2):147-55.
26. Chaddock JA, Purkiss JR, Friis LM, Broadbridge JD, Duggan MJ, Fooks SJ, Shone CC, Quinn CP, Foster KA. Inhibition of vesicular secretion in both neuronal and nonneuronal cells by a retargeted endopeptidase derivative of Clostridium botulinum neurotoxin type A. *Infect Immun*. 2000;68(5):2587-93.
27. Burstein R, Zhang X, Levy D, Aoki KR, Brin MF. Selective inhibition of meningeal nociceptors by botulinum neurotoxin type A: therapeutic implications for migraine and other pains. *Cephalalgia*. 2014;34(11):853-69.
28. Shimizu T, Shibata M, Toriumi H, Iwashita T, Funakubo M, Sato H, Kuroi T, Ebine T, Koizumi K, Suzuki N. Reduction of TRPV1 expression in the trigeminal system by botulinum neurotoxin type-A. *Neurobiol Dis*. 2012;48(3):367-78.
29. Terenghi G, Chen S, Carrington AL, Polak JM, Tomlinson DR. Changes in sensory neuropeptides in dorsal root ganglion and spinal cord of spontaneously diabetic BB rats. A quantitative immunohistochemical study. *Acta Diabetol*. 1994;31(4):198-204.
30. Marinelli S, Vacca V, Ricordy R, Ugenti C, Tata AM, Luvisetto S, Pavone F. The analgesic effect on neuropathic pain of retrogradely transported botulinum neurotoxin A involves Schwann cells and astrocytes. *PLoS One*. 2012;7(10):e47977.
31. Huang PP, Khan I, Suhail MS, Malkmus S, Yaksh TL. Spinal botulinum neurotoxin B: effects on afferent transmitter release and nociceptive processing. *PLoS One*. 2011;6(4):e19126.
32. Munoz A, Somogyi GT, Boone TB, Smith CP. Central inhibitory effect of intraventrically applied botulinum toxin A in chronic spinal cord injury. *Neurobiol Urodyn*. 2011;30(7):1376-81.
33. da Silva LB, Poulsen JN, Arendt-Nielsen L, Gazerani P. Botulinum neurotoxin type A modulates vesicular release of glutamate from satellite glial cells. *J Cell Mol Med*. 2015;19(8):1900-9.
34. Piotrowska A, Popiolek-Barczyk K, Pavone F, Mika J. Comparison of the Expression Changes after Botulinum Toxin Type A and minocycline administration in lipopolysaccharide-stimulated rat microglial and astroglial cultures. *Front Cell Infect Microbiol*. 2017;7:141.
35. Kumar R. Therapeutic use of botulinum toxin in pain treatment. *Neuronal Signal*. 2018;2(3):NS20180058.